

Management of chondrosarcomas localized to phanaxes

Chondrosarcomas localized to phanaxes

Recep Öztürk¹, Şefik Murat Arıkan¹, Emre Özcanlağan², Bedii Şafak Güngör¹, Mehmet Fatih Ekşioğlu¹¹From Department of Orthopaedics and Traumatology, Ankara Oncology Training and Research Hospital,²From Department of Orthopaedics and Traumatology, Kahramanmaraş Necip Fazıl Şehir Hastanesi, Ankara, Turkey

Abstract

Aim: The aim of this study is to determine the modalities and clinical characteristics in the treatment of 5 patients who had a diagnosis of chondrosarcoma of the phalanx. Material and Method: Clinical findings, treatment methods and failures of 5 patients with phalangeal chondrosarcoma who applied between 2008-2016 were evaluated retrospectively. Results: The mean age at diagnosis was 56.2 + 26.6 std (range 19-81) in 3 male (60.0%) and 2 female (40.0%) patients. The mean tumor size was 4.4cm + 1.1std (range 3-6). The mean duration of postoperative follow-up was 57.8 months (range 18-101 months). Four of these patients had a low grade and 1 had high-grade disease. Two patient underwent finger amputation, 3 patient underwent ray amputation. Microscopic surgical margins were negative in all patients. A superficial infection developed in amputation stump in 1 patient. None of the patients received chemotherapy/radiotherapy. Pulmonary metastasis developed in one patient's follow-up. Discussion: Malignancy should be ruled out in long-standing swellings that localized in phalanxes. Screening of metastasis must be done in patients with phalangeal chondrosarcoma and wide resection should be applied in these patients for reducing local recurrence and metastatic risk.

Keywords

Fingers; Chondrosarcoma; Metatarsus; Amputation; Chemotherapy

DOI: 10.4328/ACAM.20004 Received: 18.03.2019 Accepted: 10.04.2019 Published Online: 13.04.2019 Printed: 01.05.2020 Ann Clin Anal Med 2020;11(3):171-174

Corresponding Author: Recep Öztürk, Dr Abdurrahman Yurtaslan Ankara Oncology Training And Research Hospital, Demetevler Mah. Vatan Cad, 06200 Yenimahalle, Ankara, Turkey.

GSM: +905054634794 F.: +90 3123360909 E-Mail: ozturk_recep@windowslive.com

ORCID ID: <https://orcid.org/0000-0002-6753-9321>

Introduction

Chondrosarcomas (CS) are cartilage derived tumors and they occur rarely. They constitute 9% of primary tumors of the bone [1]. The most common localization of CS are the pelvis, proximal femur, and humerus [2]. Chondrosarcomas have rarely been reported in hands and feet [3].

Phalangeal chondrosarcomas are occasionally seen in adults between 5-7 decades and there is minimal male predilection [4,5]. CS are generally slow-growing, locally aggressive tumors with late-onset of metastasis [5].

In patients with chondrosarcoma, survival and metastatic potential are correlated with histologic grade. In grade I, grade II and grade III chondrosarcomas, 10-year survival rates were reported as 83%, 64% and 29 % respectively [6].

In the treatment of phalangeal chondrosarcomas, radical resection, including low-grade tumors, is recommended due to high recurrence rates after intralesional curettage therapy [7,8].

Chemotherapy is very ineffective in chondrosarcomas and radiation therapy is usually used only for palliation of patients with tumors that are not responding to surgical resection [9].

In this article, the clinical characteristics of 5 patients with phalangeal chondrosarcoma were evaluated, the treatment modalities were determined and the treatment results were discussed.

Material and Methods

Patients who were treated due to phalangeal chondrosarcoma in orthopedic oncology clinic of our hospital between 2008-2016 were retrospectively evaluated.

All the participants who are legally responsible or first-degree relatives of the patient in the study gave their informed consent prior to the commencement of the research. Written informed consent was obtained from the patient's legal custodian or first-degree relatives for publishing the individual medical records.

All patients' anamnesis, physical examination, postero-anterior chest X-ray, lung computed tomography, X-ray and MRI examinations of the affected extremity and routine laboratory examinations were evaluated. The imaging studies of CS of the hands and feet were reviewed by one musculoskeletal radiologist in consensus to identify imaging features by radiography. Pathological material was evaluated by an experienced musculoskeletal pathologist.

All patients were evaluated in terms of age at diagnosis, primary tumor location, the time before diagnosis, symptoms, and findings, tumor size, type of surgical procedure, chemotherapy, radiotherapy and treatment failures.

The clinical and demographic features of the patients were tabulated and summarized.

Results

Of the patients, 3 were male (60%) and were 2 female (40 %), mean age at diagnosis was 56.2+26.6 std (range 19-81). All patients applied with the primary tumor and all patients had localized disease at onset.

Mean preoperative symptom duration was 96.0 months + 50.1 std (range 48-180 mo).

The first case was a 19-year-old female who described a medial swelling on the forefoot which had been present for about 7 years and grew rapidly in the last 3 months and started to develop pain. In the AP and lateral X-rays of the patient, there was an aggressive mass in the bone that had a widespread to soft tissues, had "popcorn" style soft tissue calcification and couldn't be seen borders clearly. In the MRI, heterogeneous hy-

pointense areas were observed on T1W images; In STIR images, low-signal areas that likely to represent calcification were observed in high-signal areas. Early contrast enhancement areas were present in the contrast study. Spreading to soft tissue and early contrast enhancement of the lesion provided a departure from other tumors involving chondroid matrix that show benign features. Incisional biopsy was done under spinal anesthesia. Histopathological examination revealed a low-grade CS. First ray resection was performed (figure 1 a-d).

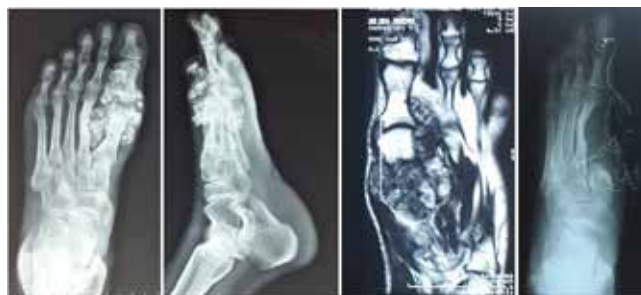

Figure 1. case no.1: chondrosarcoma around the first MTP joint, in the radiograph and MRI images, aggressive expansile tumoral lesions stemmed from the first metacarpal bone with the apparent extension to the soft tissue and having chondroid matrix is presented. a) ap x-ray b) lateral x-ray c) coronal + axial MRI section d) postoperative ap x-ray

The second case was a 38 years old male patient. The patient has had swelling in distal of the second phalanx of the foot for 8 years. The patient applied due to post-traumatic pain and rapid growth 5 months ago. A mass with chondroid calcifications was observed in the AP and lateral radiographs of the patient with prominent expansile features of the 2nd finger distal phalanx. The transition zone of the cortex was narrow, the inner part of the cortex was thin partly (endosteal scalloping). MRI was performed to demonstrate soft tissue segregation and contrast enhancement of the mass, and it was found that the lesion had no soft tissue outgrowth and additionally the middle phalanx was affected. There was heterogeneous contrast enhancement in the post-contrast examination. Because of endosteal scalloping and the destruction of the middle phalanx, chondrosarcoma was primarily thought to be present in the patient. In addition to that, there was enchondroma in the differential diagnosis due to age and lesion placement. The patient underwent incisional biopsy under spinal anesthesia. Histopathological examination revealed a low-grade CS. Disarticulation was performed from the 2nd PIF joint level (figure 2 a-d).

The third case was a 67-year-old male patient. The patient described slow growing painless swelling which developed around

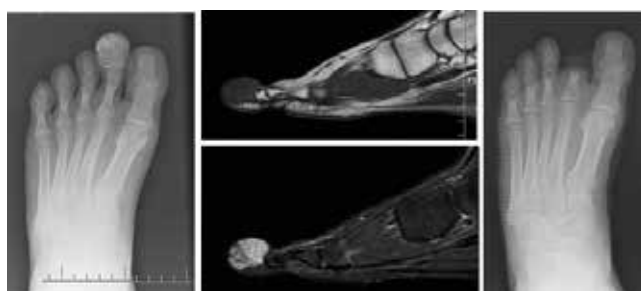


Figure 2. Case no 2: chondrosarcoma of the second finger of the foot. Expansile, mixed lytic-sclerotic tumoral lesion containing chondroid matrix with relatively intact borders leading to sclerosis and thinning of the cortex at the level of second distal phalanx of the foot is viewed. The tumor with these characteristics is radiologically resembling enchondroma. a) preoperative ap x-ray b and c) preoperative sagittal MRI d) postoperative ap xray

the phalanx-metatarsus for about 15 years. On the X-rays, a mass was observed around the proximal and middle of 5th phalanx which had a lobulated contour and distinct expansile features, followed by popcorn calcifications. Mass borders could not be clearly separated from neighboring bone structures. Chondrosarcoma was considered primarily because of the destruction of adjacent bones and chondroid calcification. On MRI examination, destruction of bone with high T2 signal (typical appearance of cartilaginous tissue tumor), chondroid matrix, cortical thinning and thickening suggested chondrosarcoma. The patient underwent incisional biopsy under spinal anesthesia. Histopathological examination revealed a low-grade CS. The patient underwent fifth ray resection.

The fourth case was an 81-year-old male patient. There was painless swelling in the distal part of the first phalanx of the left hand for about 2 years. The patient applied with hemorrhagic nail disorder and ulcer wound that required nail removal twice 24 and 18 months ago. A permeative lytic lesion that had lobulated contour, spread into soft tissue and included minimal calcification areas were observed on the imaging examination. Chondrosarcoma was primarily thought due to the patient's age and aggressive-looking mass. Under local anesthesia, the patient underwent incisional biopsy from the tumoral soft tissue in the ulcer wound. Histopathological examination revealed high-grade CS. The patient underwent wide resection.

The fifth case was a 76-year-old female patient. The patient has had swelling around 4th phalanx and metacarpal of hand about 6 years. Rapid growth and pain on the swelling started in the last 6 months. Near of the fourth proximal phalanx and metacarpophalangeal joints, an expansile lytic bone lesion which had a thin sclerotic rim leading to cortical thinning and thickening, affecting the proximal phalanx and metacarpal joint was observed. There was no appearance of the lesion suggesting soft tissue spread. Chondrosarcoma was thought primarily due to endosteal scalloping, bone destruction and advanced age, painful swelling without fracture. An incisional biopsy was performed under general anesthesia. Histopathological examination revealed a low-grade CS. The patient underwent a fourth ray resection.

Microscopic surgical margins were negative in all patients. One patient (case no 4) did not accept screening tests (e.g. thorax ct) and possible chemotherapy treatment because of advanced age. All patients are followed up after surgery. None of the patients received chemotherapy/radiotherapy. In 1 case (case no 2), superficial infection developed in amputation stump, debridement + suturation was performed, no complication dependent on surgery occurred in any other patient. The mean postoperative follow-up duration was 57.8 months (18-101 months) (table 2). One patient (case no 4), developed severe breathlessness and

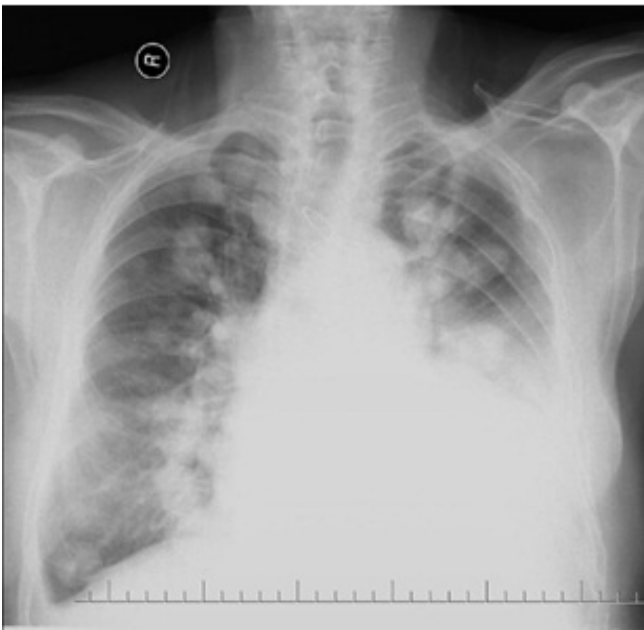

Figure 3. Case no 4: chondrosarcoma of the first finger of the hand. Multiple calcific metastatic lesions are seen in the chest x-rays on the application of 17th month postoperatively.

general impairment at the 17th month after surgery. A large number of scattered and calcified masses were observed in both lungs on PA chest X-ray. In patients with chondrosarcoma, these findings made us think of metastasis (figure 3). The patient died due to pulmonary metastases on follow-up 18th month. No recurrence/metastasis was detected in any other patient's follow-up (table 2).

The other 4 patients (case no 1,2,3 and 5) are still under our follow-up without the disease.

Discussion

CS are cartilage derived tumors and they occur rarely. They constitute 9% of primary tumors of the bone [1]. The most common localization of CS are the pelvis, proximal femur, and humerus [2]. Chondrosarcomas have rarely been reported in hands and feet [3].

Table 2. Follow-up times and treatment results

Case no	KT	RT	Duration before (months)	Follow up (months)	Recur-rence	metas-tasis	Last condition
1	-	-	84	77	-	-	Free of disease
2	-	-	96	24	-	-	Free of disease
3	-	-	180	101	-	-	Free of disease
4	-	-	48	18	-	Lung	ex
5	-	-	72	69	-	-	Free of disease

Table 1. Demographic data, surgical treatments and complications

Case no	Age (years)	gender	location	Grade	Size (cm)	Resection type	Surgical margin	morbidity	treatment
1	19	female	Around 1st mtp of foot	Low	6	Ray resection	negative	-	-
2	38	Male	Distal phalanx of the 2nd finger of foot	Low	3	Disarticulation from PIF joint level	negative	Superficial infection	Debridgement + suturation
3	67	male	Around mtp joint of 5th finger of the foot.	Low	5	Ray resection	negative	-	-
4	81	male	Distal phalanx of the 1st finger of the hand	High	4	Wide resection	negative	-	-
5	76	female	Around MCP joint of 4th finger of the hand.	Low	4	Ray resection	negative	-	-

Primary chondrosarcoma is the third most common malignancy of bone after myeloma and osteosarcoma, but the small bones of the hands and feet are very rarely involved by chondrosarcoma [10].

Phalangeal chondrosarcomas usually present in the adults from 5th to 7th decade [5]. In our study the mean age was 56.2 as well, however, 4 of 5 patients were out of the interval between 50-70 (table 1).

When the literature was reviewed, it is seen that males (52%) were affected by this disorder slightly more [4]. In our study, the ratio of males were 60% likewise.

Unlike other localizations, pain is not frequent in chondrosarcomas where localized on distal of the extremities. The symptoms of presentation are painless or painful swelling [5,11]. In addition, a case presenting with thumb finger dystrophy has been reported in the literature [7]. In our study, there was painless swelling in one case (case no 3), painful swelling in 3 cases (cases no 1, 2 and 5) and nail disorder in one case (case no 4). Phalangeal chondrosarcomas have recently been categorized as a different neoplasm from classical hand chondrosarcomas, and high local aggressive behavior and recurrence risk with minimal metastatic potential [5]. However, Fayad et al. Reported 28 metastatic cases of hand and foot chondrosarcoma in a recent systematic literature review [4]. In our study, metastasis was present in one of 5 patients.

Because of chondrosarcomas are cartilage-producing tumors, they appear expansive, lytic lesions with chondroid matrix calcifications on x-ray or tomographic examination and the mass appears as a signal-free area within the high T2 signal on MRI. It can lead to thinning and thickening of the bone cortex (endosteal scalloping) [2]. They generally present as large masses and soft tissue spread can be seen.

The differentiation of phalangeal chondrosarcomas from benign chondroid tumors is sometimes difficult radiologically. In the higher histologic grade, less matrix mineralization is observed and permeative lytic appearance is seen [3]. Patient age, the presence of soft tissue spreading, large size, endosteal scalloping, early contrast enhancement pattern on dynamic MRI examination are very effective in distinguishing from enchondroma [2,12]. Two of our cases had soft tissue spread. In the bone-limited lesions, endosteal scalloping, cortical thickening, early contrast enhancement, and sometimes patient's age have helped to distinguish from enchondroma.

The metastatic potential and survival of chondrosarcoma correlate with the histological grade. Reported 10-year survival rates are 83, 64 and 29% for grades I, II and III respectively [6]. The treatment of choice of early chondrosarcoma is radical resection. Chemotherapy is very ineffective, and radiation therapy is usually used only for palliation of patients with tumors that are not proper to surgical resection. Patients with metastatic chondrosarcoma, represent a difficult therapeutic challenge [13,14].

Recurrence rates of 22% to 62.5% have been reported in surgical treatment, especially only in curettage patients [7]. Therefore, radical excision and amputation are generally recommended even in lower grade CS [8]. In our study which included 4 of 5 patients who had a low-grade tumor, all cases underwent radical surgery with negative surgical borders (table 1).

The present study had several limitations. It was designed as a retrospective study, and the number of patients was low because of the fact that the disease is observed rarely. The authors have indicated no significant interest with commercial supporters.

Conclusion

Malignancy should be ruled out in long-standing swellings that are localized in phalanxes even if they are asymptomatic. Screening of metastasis must be done in patients with phalangeal chondrosarcoma and wide resection should be applied in these patients to reduce local recurrence and metastatic risk.

Scientific Responsibility Statement

The authors declare that they are responsible for the article's scientific content including study design, data collection, analysis and interpretation, writing, some of the main line, or all of the preparation and scientific review of the contents and approval of the final version of the article.

Animal and human rights statement

All procedures performed in this study were in accordance with the ethical standards of the institutional and/or national research committee and with the 1964 Helsinki declaration and its later amendments or comparable ethical standards. No animal or human studies were carried out by the authors for this article.

Funding: None

Conflict of interest

None of the authors received any type of financial support that could be considered potential conflict of interest regarding the manuscript or its submission.

References

1. Bashir SI, Gupta R, Khan HN, Ahmed R, Mohd A, Salaria AQ. Trans-articular chondrosarcoma grade 2 of proximal phalanx resulting in its fracture along with the destruction of middle phalanx of 2 toe right foot: a case report and review of the literature. *Cases J*. 2009; 6(2): 7488. DOI:10.4076/1757-1626-2-7488.
2. Mondal SK. Chondrosarcoma of the distal phalanx of the right great toe: report of a rare malignancy and review of literature. *J Cancer Res Ther*. 2012; 8(1): 123-5. DOI: 10.4103/0973-1482.95191.
3. O'Connor MI, Bancroft LW. Benign and malignant cartilage tumors of the hand. *Hand Clin*. 2004; 20(3): 317-23. DOI: 10.1016/j.hcl.2004.03.019.
4. Fayad LM, Ahlawat S, Khan MS, McCarthy E. Chondrosarcomas of the hands and feet: A case series and systematic review of the literature. *Eur J Radiol*. 2015; 84(10): 2004-12. DOI: 10.1016/j.ejrad.2015.06.026.
5. Patil S, de Silva MV, Crossan J, Reid R. Chondrosarcoma of small bones of the hand. *J Hand Surg Br*. 2003; 28: 602-8.
6. Bovee JV, van der Huel RO, Tamminiau AH, Hogendoorn PC. Chondrosarcoma of the phalanx: A locally aggressive lesion with minimal metastatic potential. A report of 35 cases and a review of the literature. *Cancer*. 1999; 86: 1724-32.
7. Au S, Juhl ME, Emmadi R, Kronic AL. Nail dystrophy as a presentingsign of a chondrosarcoma of the distal phalanx - case report and review of the literature. *Acta Derm Venereol*. 2015; 95(8): 1026-7. DOI: 10.2340/00015555-2118
8. Murphey MD, Walker EA, Wilson AJ, Kransdorf MJ, Temple HT, Gannon FH. From the archives of the AFIP: imaging of primary chondrosarcoma : radiologic-pathologic correlation. *Radiographics*. 2003; 23 (5): 1245-78. DOI:10.1148/rgr.265065084.
9. Debruyne PR, Dumez H, Demey W, Gillis L, Sciort R, Schöffski P. Recurrent low- to intermediate grade chondrosarcoma of the thumb with lung metastases: an objective response to trofosamide. *Onkologie*. 2007; 30(4): 201-4. DOI:10.1159/000099988
10. Öztürk R, Arıkan ŞM, Bulut EK, Kekeç AF, Çelebi F, Güngör BŞ. Distribution and evaluation of bone and soft tissue tumors operated in a tertiary care center. DOI:10.1016/j.aott.2019.03.008.
11. Ogoose A, Unni KK, Swee RG, May GK, Rowland CM, Sim FH. Chondrosarcoma of small bones of the hands and feet. *Cancer*. 1997; 80(1): 50-9.
12. Varma DG, Ayala AG, Carrasco CH, Guo SQ, Kumar R, Edeiken J. Chondrosarcoma: MR imaging with pathologic correlation. *Radiographics*. 1992; 12(4): 687-704. DOI:10.1148/radiographics.12.4.1636034
13. Öztürk R, Arıkan ŞM, Toğral G, Güngör BŞ. Malignant tumors of the shoulder girdle: Surgical and functional outcomes. DOI: : 10.1177/2309499019838355.
14. Somers J, Faber LP. Chondroma and chondrosarcoma. *Semin Thorac Cardiovasc Surg*. 1999; 11: 270-7.

How to cite this article:

Öztürk R, Arıkan ŞM, Özcanlağan E, Güngör BŞ, Ekşioğlu MF. Management of chondrosarcomas localized to phanaxes. *Ann Clin Anal Med* 2020;11(3):171-174